

Case Study: Diabetic retinopathy – type 1 diabetes

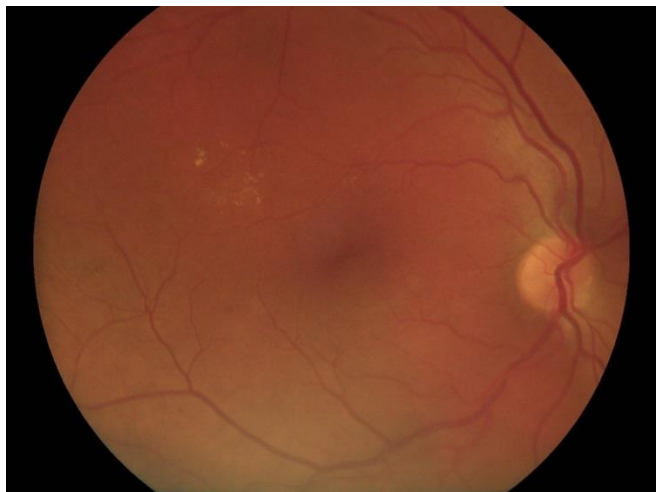
Prof. Eija Vesti, MD, PhD, FEBO
Chief Physician, Ophthalmology Department
Turku University Hospital, Finland

History

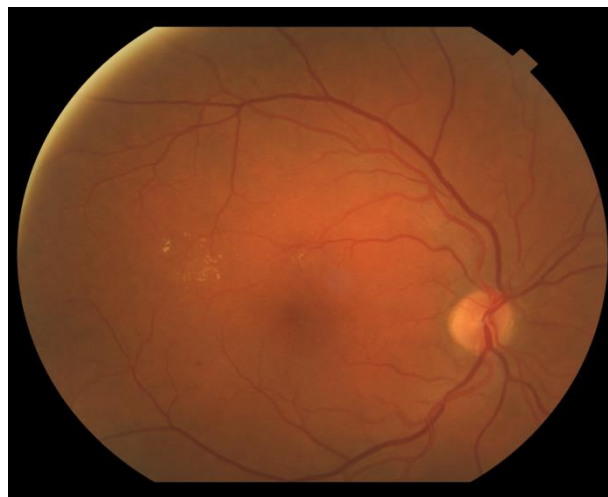
The patient is a 51-year-old female with type 1 diabetes (diagnosed in year 1986). Recently the patient's glucose levels have been fluctuating and insulin doses have been adjusted accordingly. Patient is reported to have also diabetic nephropathy.

Examination

During a routine screening for diabetic patients some retinal changes were detected and patient was referred to Turku University Hospital's ophthalmology clinic for further examination and consultation. After dilation the patient was imaged with Smartscope PRO hand-held retinal camera and also with Topcon camera. Images attached show similar findings with some exudates.



Picture 1: Fundus image taken with Smartscope PRO camera.



Picture 2: Fundus image taken with Topcon camera.